

Disappearing liver mets : new solutions of an old problem

Francesco Ardito

Unità di Chirurgia Epatobiliare
Direttore : Prof. F. Giuliante
Fondazione Policlinico Universitario A. Gemelli, IRCCS
Università Cattolica, Roma



Liver resection for colorectal metastases

- Imaging after neo-adjuvant chemotherapy can be challenging due to :

  - Radiological response of liver metastases

  - Parenchymal effects of chemotherapy

    - *Lower density of the liver parenchyma*
    - *Decreased liver-to-lesion contrast*
    - *Disappearing lesions*

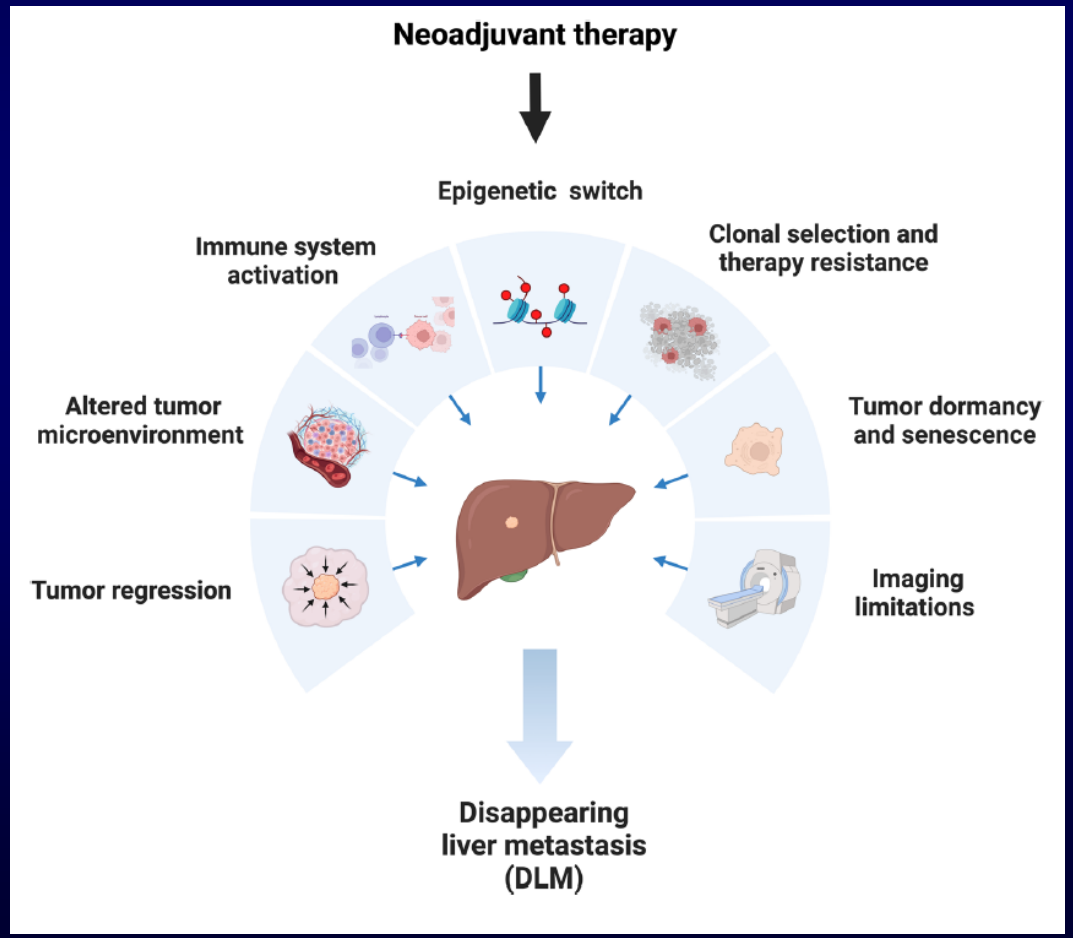

44 yrs-old female patient
synchronous liver metastases in sigmoid cancer

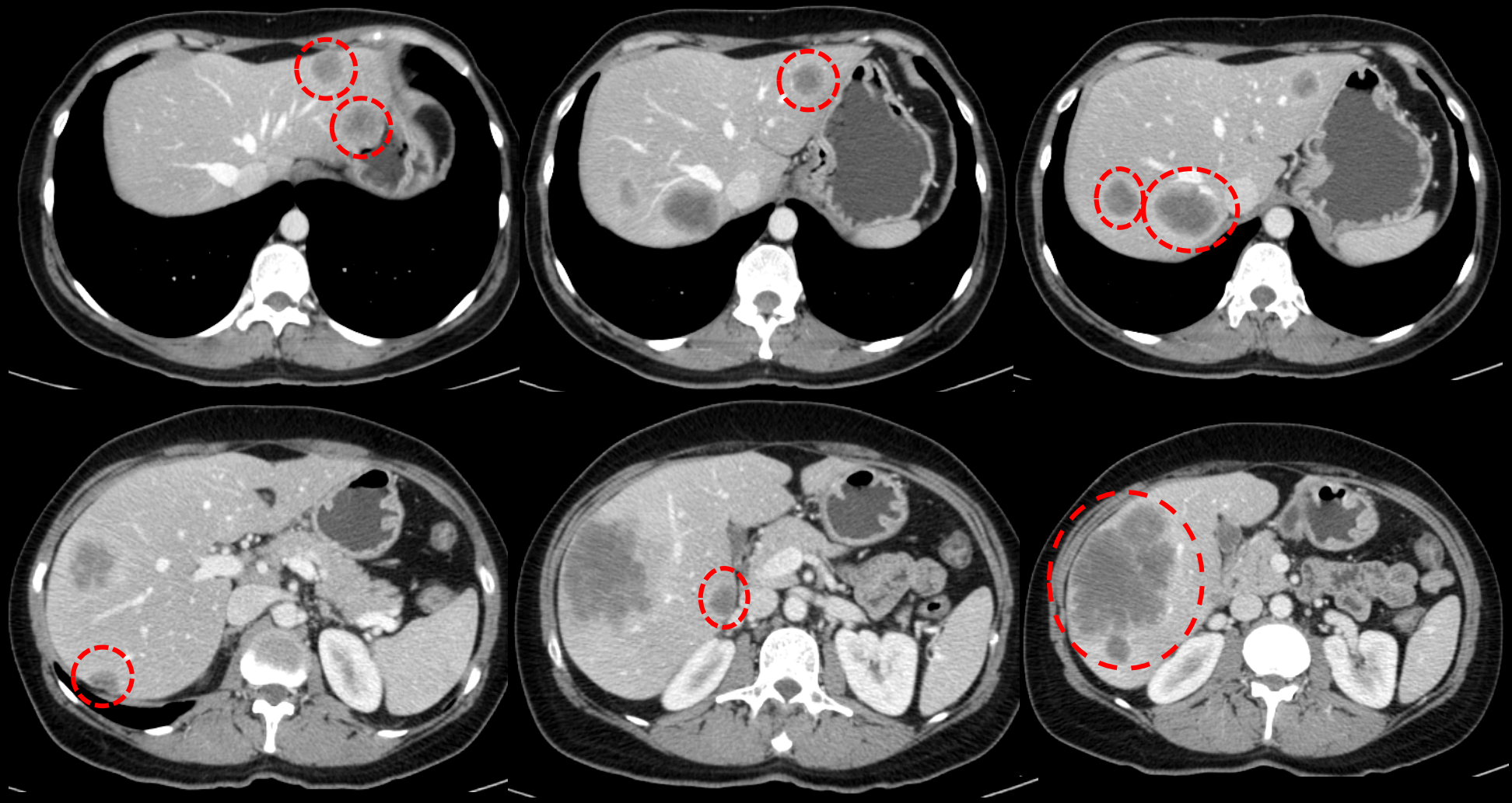

CT after chemotherapy : FOLFIRI + Bevacizumab (12 courses)

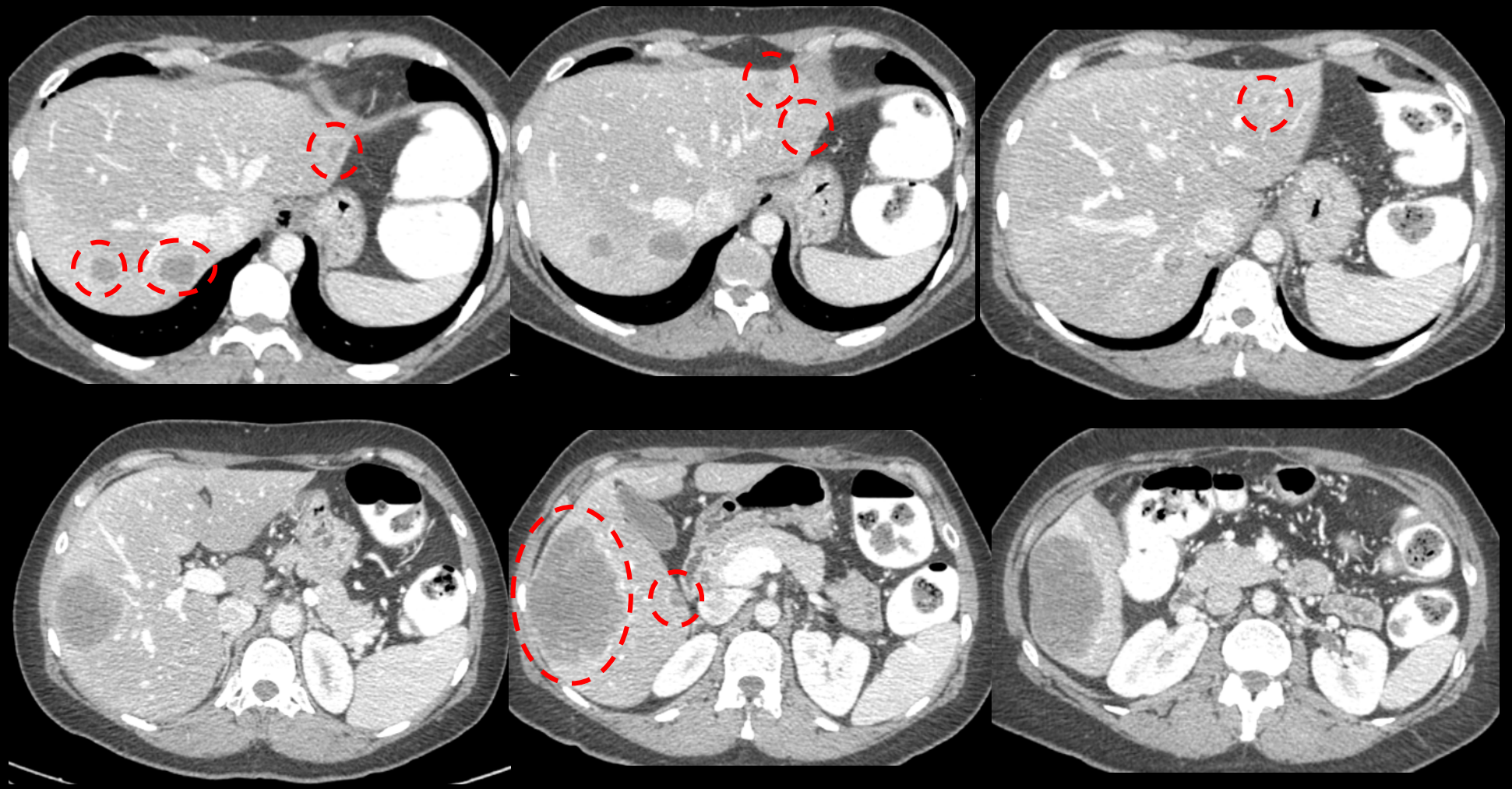

66 yrs-old male patient ; FOLFIRI + Cetuximab 14 cycles

CT before CHT

CT after CHT

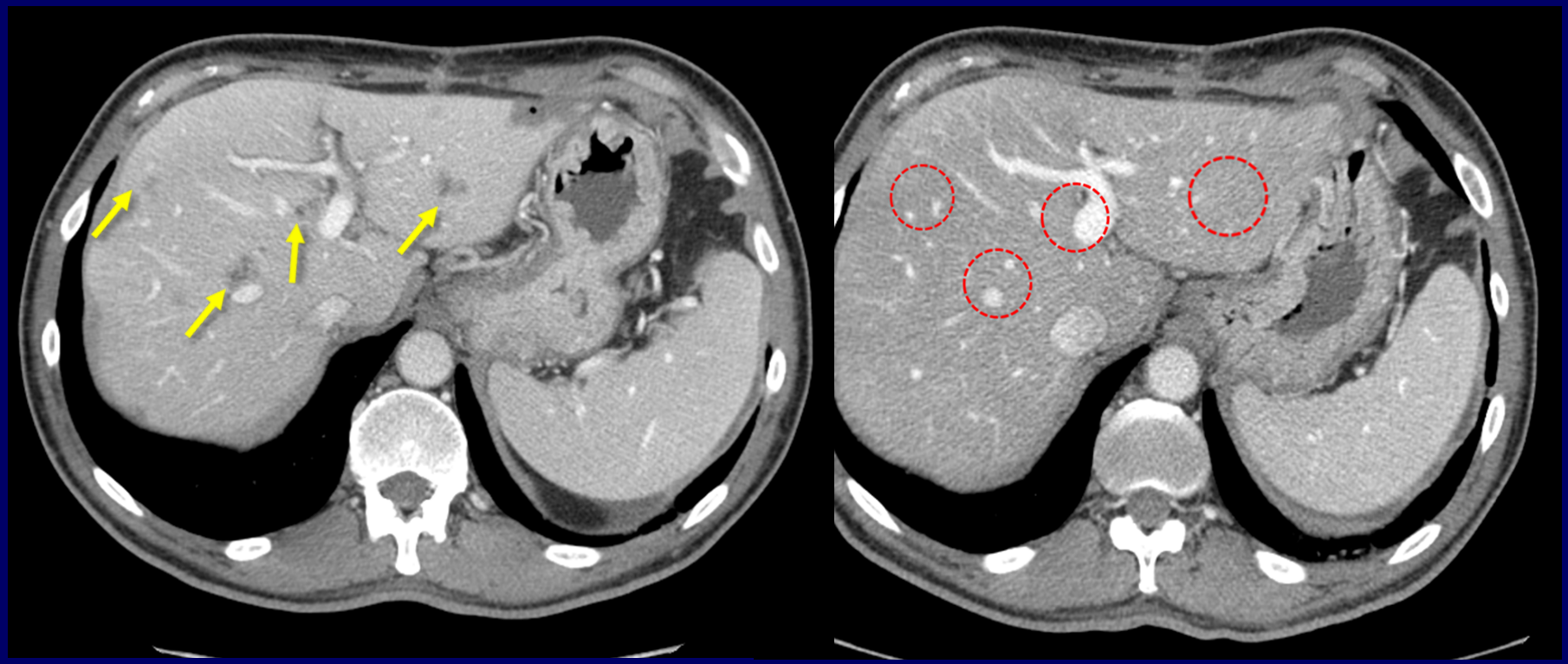



Disappearing colorectal liver metastases (DLM)

- 5 – 25 % of patients who undergo preoperative systemic chemotherapy

multiple CRLM
size < 1 cm
prolonged preoperative CHT

} Independent predictors of developing DLM

Management of disappearing colorectal liver metastases: an international survey

Laleh G. Melstrom[1], Susanne G. Warner[1], Paul Wong[1], Virginia Sun[2], Mustafa Raoof[1], Gagandeep Singh[1], Kenneth D. Chavin[3], Yuman Fong[1], Rene Adam[4] & Thomas J. Hugh[5]

HPB 2021

- 226 respondents (AHPBA , IHPBA and ANZHPBA)

- Nearly all have experienced disappearing CRLM (99 %)

When is a Ghost Really Gone? A Systematic Review and Meta-analysis of the Accuracy of Imaging Modalities to Predict Complete Pathological Response of Colorectal Cancer Liver Metastases After Chemotherapy

Ann Surg Oncol 2021

Hala Muaddi, MD MSc[1], Stephanie Silva, MD[2], Woo Jin Choi, MD[1], Natalie Coburn, MD PhD[1,2], Julie Hallet, MD MSc[1,2], Calvin Law, MD PhD[1,2], Helen Cheung, MD PhD[3], and Paul J. Karanicolas, MD PhD[1,2]

- Suboptimal imaging modalities for re-staging after neo-adjuvant therapy may result in an overestimation of the number of DLM

- The definition of DLM critically depends on imaging technique performance

Preoperative Imaging of Colorectal Liver Metastases After Neoadjuvant Chemotherapy: A Meta-Analysis

Charlotte S. van Kessel, MD[1,2], Constantinus F.M. Buckens, MD[2,3], Maurice A.A.J. van den Bosch, MD, PhD[2], Maarten S. van Leeuwen, MD, PhD[2], Richard van Hillegersberg, MD, PhD[1], and Helena M. Verkooijen, MD, PhD[2,3]

Ann Surg Oncol 2012

- 11 papers - 223 patients - 906 lesions
- Negative impact of chemotherapy on CT diagnostic performance

CT sensitivity

80.5% (chemonaive pts) ➡ 69.9% (after chemo)

- Contrast-enhanced MRI has the highest sensitivity (85.7%) to detect metastases after neo-adjuvant chemotherapy

Use of Imaging to Predict Complete Response of Colorectal Liver Metastases after Chemotherapy: MR Imaging versus CT Imaging[1]

Min Jung Park, MD
Nurhee Hong, MD[2]
Kyunghwa Han, PhD
Min Ju Kim, MD
Yoon Jin Lee, MD
Yang Shin Park, MD
Sung Eun Rha, MD
Sumi Park, MD
Won Jae Lee, MD
Seong Ho Park, MD
Chang Hee Lee, MD
Chung Mo Nam, ScD
Chansik An, MD
Hye Jin Kim, MD
Honsoul Kim, MD
Mi-Suk Park, MD

Radiology 2017

- Hepatocyte – specific contrast agents helps detect more CRLM than conventional MR imaging (sensitivity : 95 % vs. 87 %)

48 years old male, multiple (17) synchronous metastases

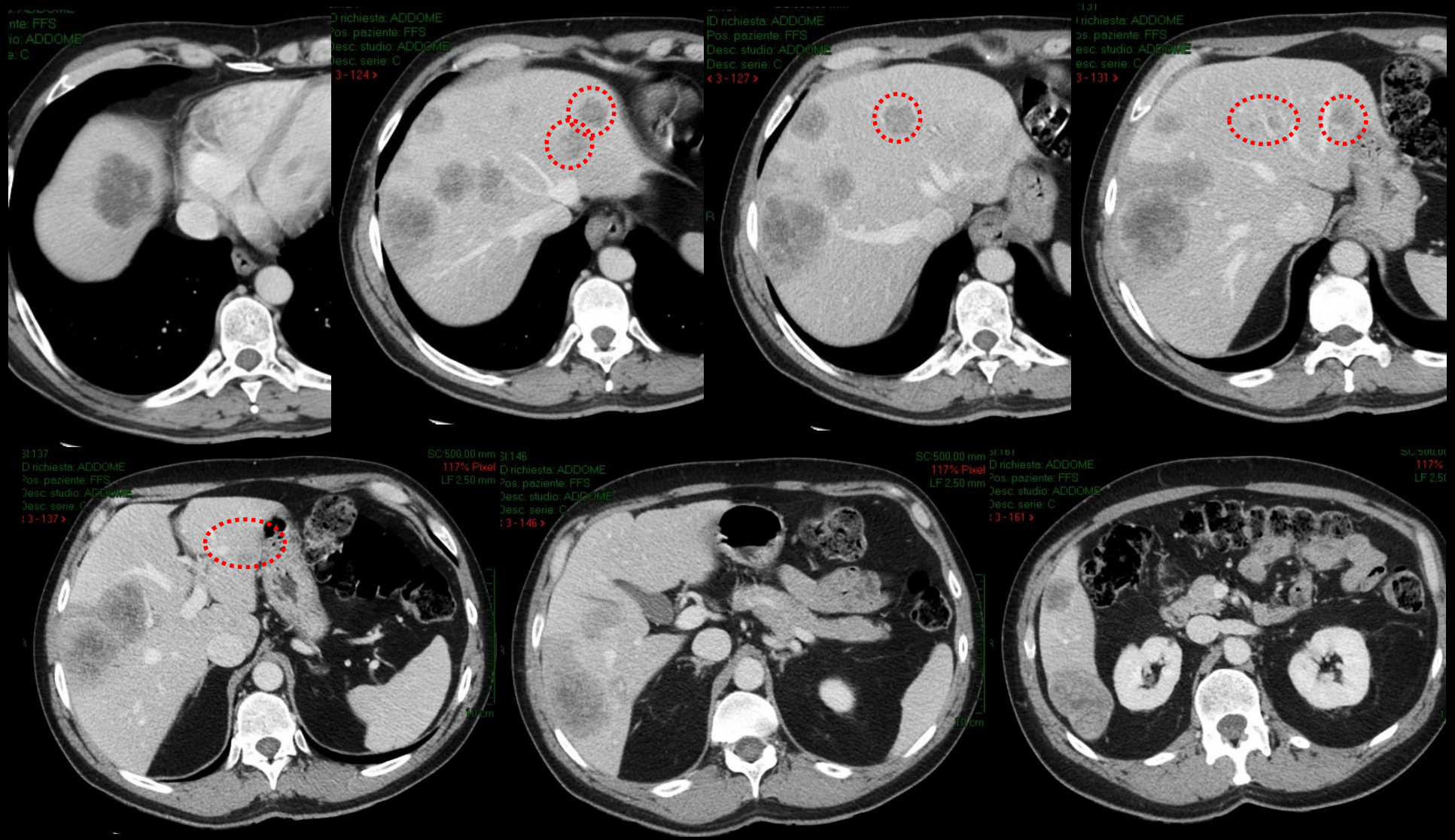

CT after CHT (FOLFOX – Panitumumab 8 courses)



MR after CHT (FOLFOX – Panitumumab 8 courses)

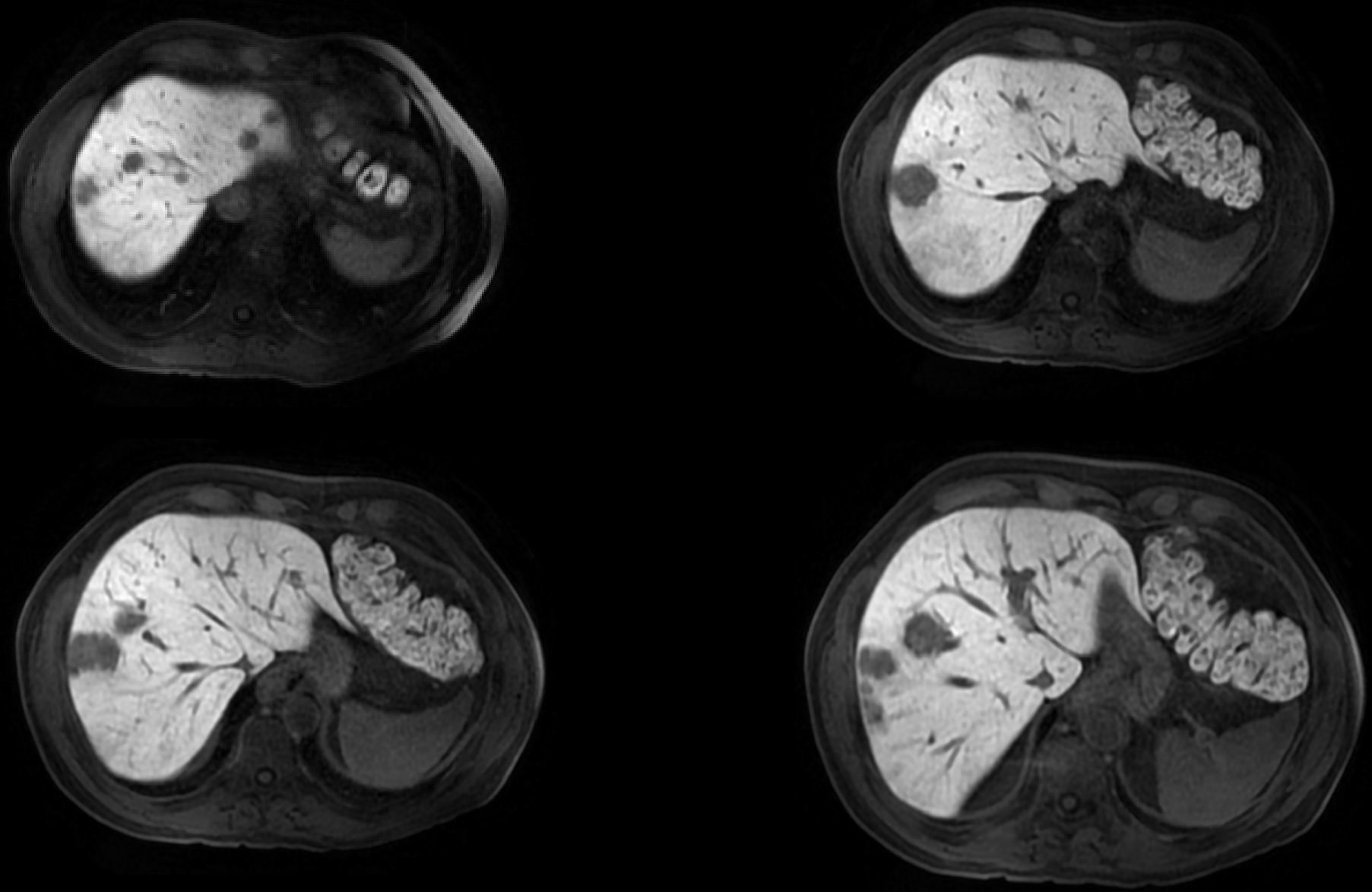

MR after CHT (FOLFOX – Panitumumab 8 courses)

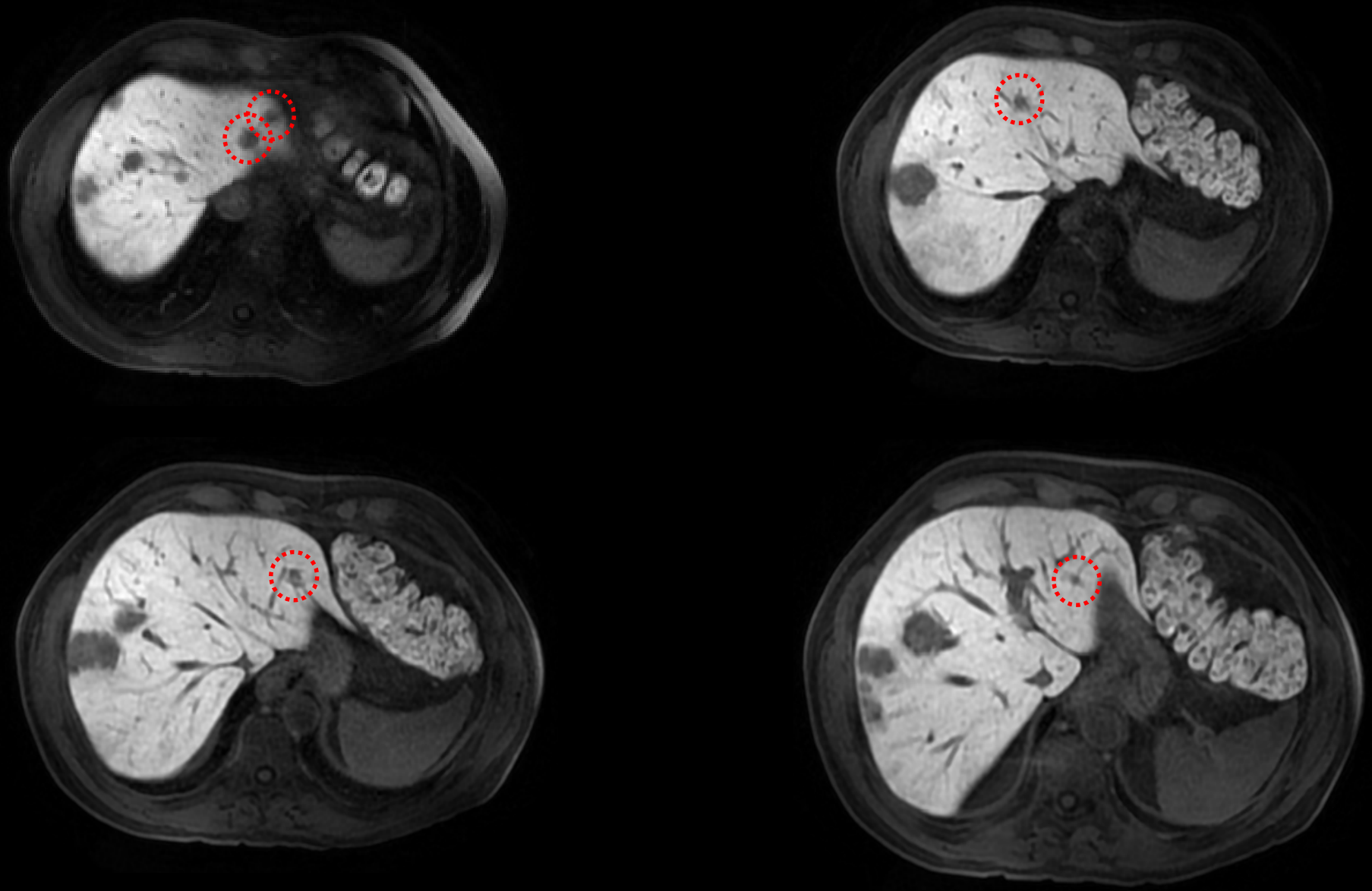

CONSENSUS STATEMENT

The multi-societal European consensus on the terminology, diagnosis and management of patients with synchronous colorectal cancer and liver metastases: an E-AHPBA consensus in partnership with ESSO, ESCP, ESGAR, and CIRSE

Ajith K. Siriwardena[1], Alejandro Serrablo[2], Åsmund A. Fretland[3], Stephen J. Wigmore[4], Jose M. Ramia-Angel[5], Hassan Z. Malik[6], Stefan Stättner[7], Kjetil Søreide[8], Oded Zmora[9], Martijn Meijerink[10], Nikolaos Kartalis[11], Mickaël Lesurtel[12], Cornelis Verhoef[13], Anita Balakrishnan[14], Thomas Gruenberger[15], Eduard Jonas[16], John Devar[17], Saurabh Jamdar[1], Robert Jones[6], Mohammad A. Hilal[18], Bodil Andersson[19], Karim Boudjema[20], Saifee Mullamitha[21], Laurents Stassen[22], Bobby V.M. Dasari[23], Adam E. Frampton[24], Luca Aldrighetti[25], Gianluca Pellino[26,27], Pamela Buchwald[19], Bengi Gürses[28], Nir Wasserberg[29], Birgit Gruenberger[30], Harry V.M. Spiers[14], William Jarnagin[31], Jean-Nicholas Vauthey[32], Norihiro Kokudo[33], Sabine Tejpar[34], Andres Valdivieso[35], René Adam[36], on behalf of the Joint E-AHPBA/ESSO/ESCP/ESGAR/CIRSE 2022 Consensus on colorectal cancer with synchronous liver metastases

HPB 2023

The term disappearing metastases is defined as

lesions present on baseline contrast MR

which are no longer visible on hepatobiliary contrast MR

after systemic chemotherapy

Intraoperative Ultrasound Staging for Colorectal Liver Metastases in the Era of Liver-Specific Magnetic Resonance Imaging: Is It Still Worthwhile?

J Oncol 2019

Serena Langella,[1] Francesco Ardito,[2] Nadia Russolillo,[1] Elena Panettieri,[2] Serena Perotti,[1] Caterina Mele,[2] Felice Giuliante,[2] and Alessandro Ferrero[1]

- 721 resected pts for CRLM (2010 – 2017)
- Preoperative workup by liver specific MR
- 489 pts resected after preoperative CHT



- DLM in 52 pts (10.6 %)

The dilemma of the disappearing colorectal liver metastases: defining international trends in management

Mudassar A. Ghazanfar[1,2], Amir Abdelhamid[1,2], Luca Aldrighetti[3], Christian Sturesson[4], Nobuyuki Takemura[5], Stephanie Truant[6], Guido Fiorentini[7], Catherine Teh[8,9,10], Ruslan Alikhanov[11], Irfan Ahmed[1,2], John Hammond[12], Alessandro Ferrero[13], Michael Silva[14], Timothy Pawlik[15], Robert Jones[16] & Mohamed Bekheit[1,2,17]

HPB 2023

- 67 liver surgeons from 25 countries
- Seven simulated scenarios of dCRLM

Scenario 1

dCRLM peripheral and in readily accessible location

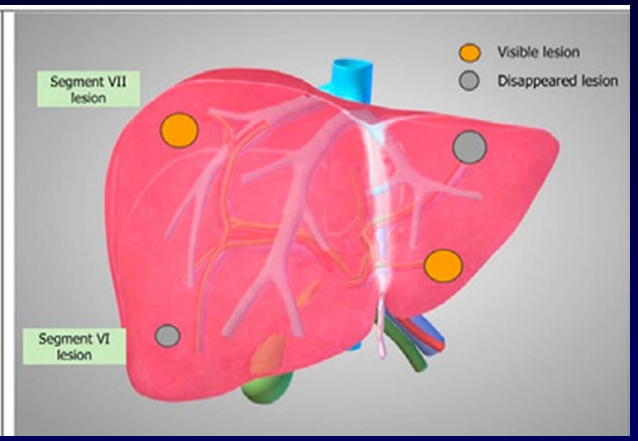

Scenario 2

dCRLM peripheral but one in more challenging location

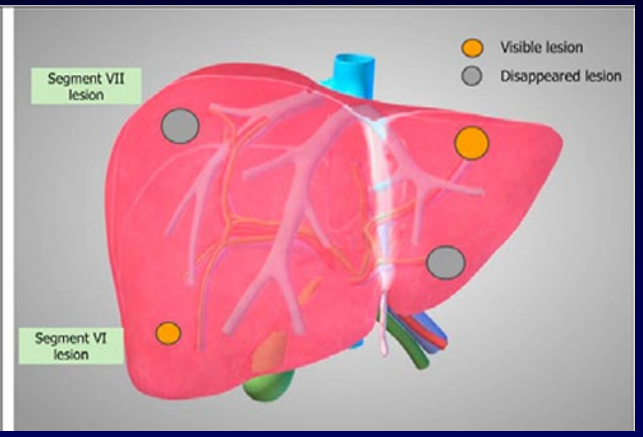

Scenario 3

One lesion dCRLM is in contact with right hepatic vein

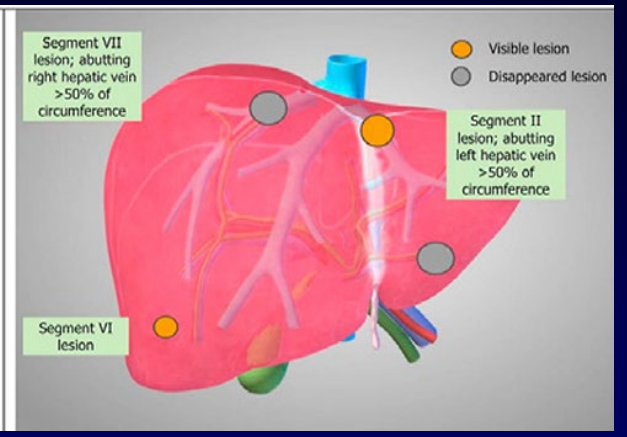

Scenario 4

One lesion dCRLM is in contact with left hepatic vein

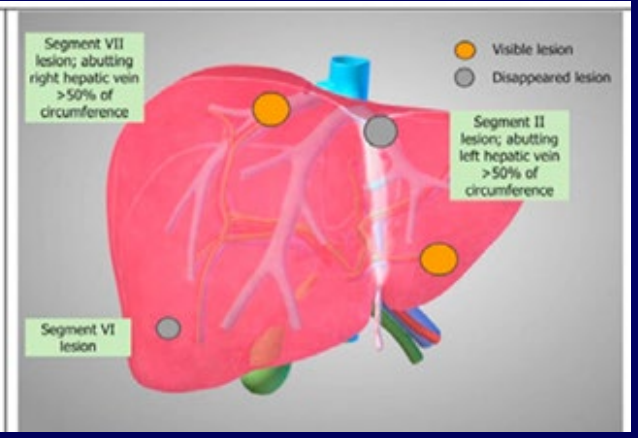

Scenario 5

Multiple lesions on right side dCRLM. Left remain detectable

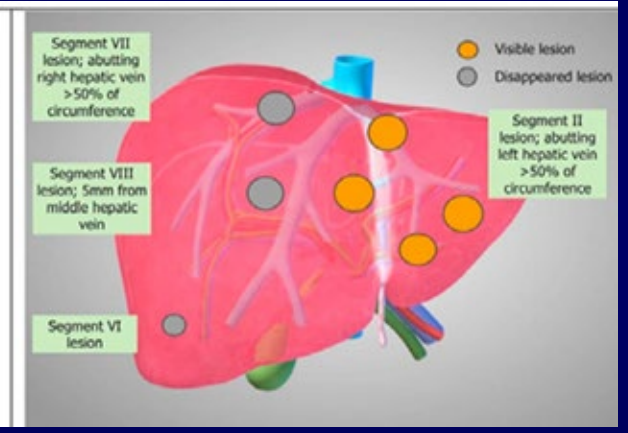

Scenario 6

One dCRLM on a major glissonian pedicle

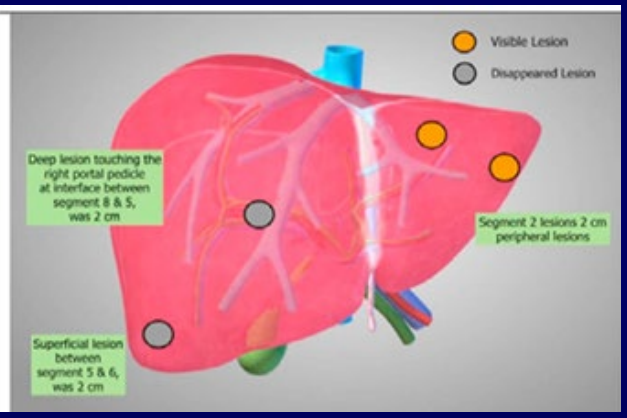

Scenario 7

All liver lesions are dCRLM

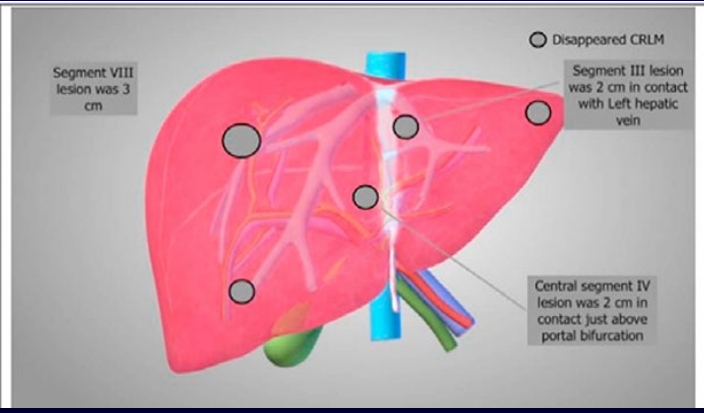

The dilemma of the disappearing colorectal liver metastases: defining international trends in management

Mudassar A. Ghazanfar[1,2], Amir Abdelhamid[1,2], Luca Aldrighetti[3], Christian Sturesson[4], Nobuyuki Takemura[5], Stephanie Truant[6], Guido Fiorentini[7], Catherine Teh[8,9,10], Ruslan Alikhanov[11], Irfan Ahmed[1,2], John Hammond[12], Alessandro Ferrero[13], Michael Silva[14], Timothy Pawlik[15], Robert Jones[16] & Mohamed Bekheit[1,2,17]

HPB 2023

- 10 management options

1) Resect All
2) Resect visible, ablate dCRLM
3) Resect visible, no treatment dCRLM
4) Resect visible, convenience resection of dCRLM
5) Ablate visible, no treatment dCRLM
6) Further chemotherapy
7) Resect some visible & dCRLM, ablate other visible and leave some dCRLM
8) Resect some dCRLM and leave others
9) Follow up only no chemo
10) Resect some dCRLM and ablate others

The dilemma of the disappearing colorectal liver metastases: defining international trends in management

Mudassar A. Ghazanfar[1,2], Amir Abdelhamid[1,2], Luca Aldrighetti[3], Christian Sturesson[4], Nobuyuki Takemura[5], Stephanie Truant[6], Guido Fiorentini[7], Catherine Teh[8,9,10], Ruslan Alikhanov[11], Irfan Ahmed[1,2], John Hammond[12], Alessandro Ferrero[13], Michael Silva[14], Timothy Pawlik[15], Robert Jones[16] & Mohamed Bekheit[1,2,17]

HPB 2023

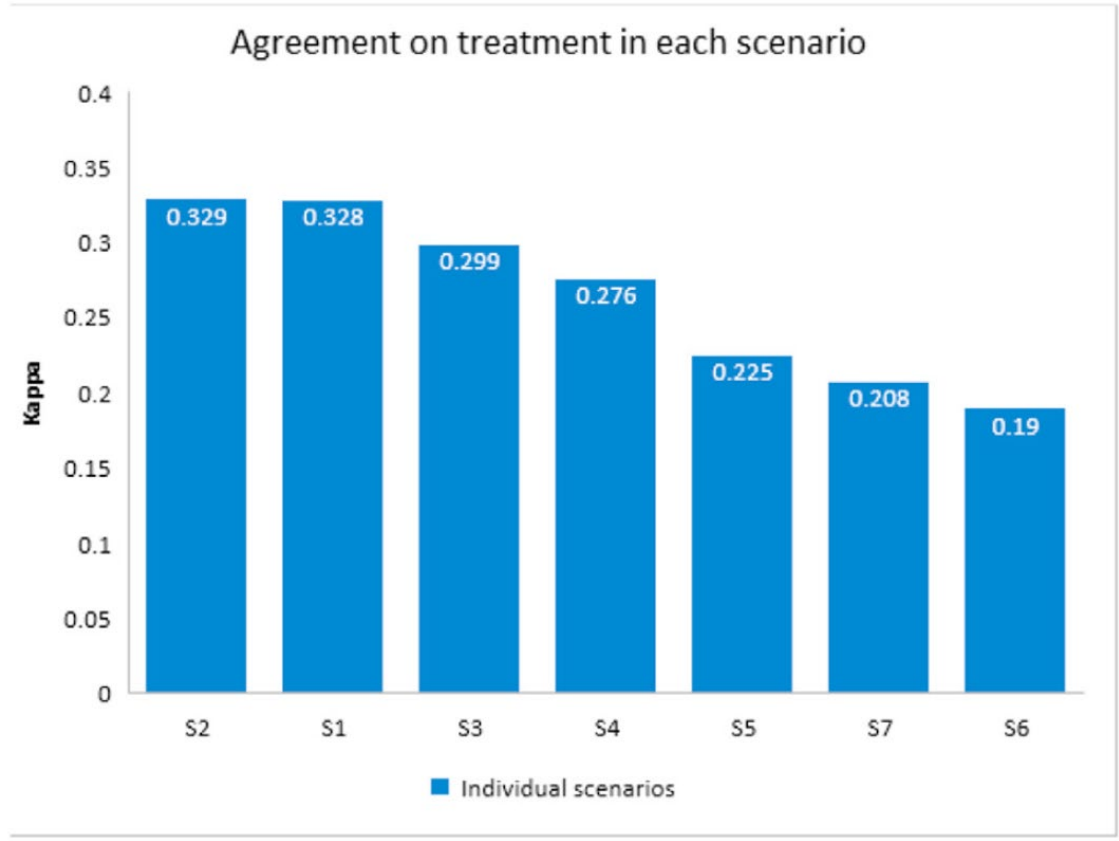

Agreement levels :

k level		
	0.00–0.20	none
	0.21–0.39	minimal
	0.40–0.59	weak
	0.60–0.79	moderate
	0.80–0.90	strong
	> 0.90	almost perfect

The dilemma of the disappearing colorectal liver metastases: defining international trends in management

Mudassar A. Ghazanfar[1,2], Amir Abdelhamid[1,2], Luca Aldrighetti[3], Christian Sturesson[4], Nobuyuki Takemura[5], Stephanie Truant[6], Guido Fiorentini[7], Catherine Teh[8,9,10], Ruslan Alikhanov[11], Irfan Ahmed[1,2], John Hammond[12], Alessandro Ferrero[13], Michael Silva[14], Timothy Pawlik[15], Robert Jones[16] & Mohamed Bekheit[1,2,17]

HPB 2023

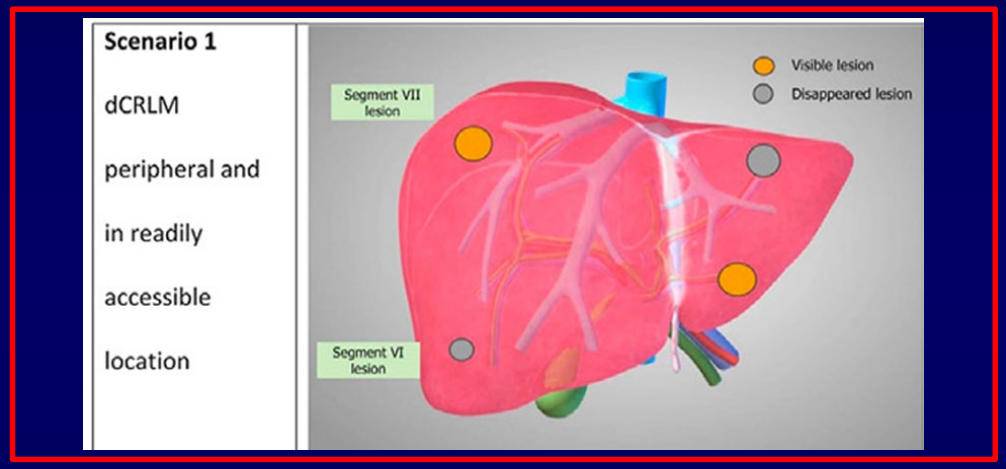

DLM not identified in the operating room with IOUS

observation (“watch and wait ”)
48 %

resect if the presumed area was superficial
31 %

Disappearing liver metastases: A systematic review of the current evidence

Diamantis I. Tsilimigras[a], Ioannis Ntanasis-Stathopoulos[b], Anghela Z. Paredes[a], Dimitrios Moris[a], Maria Gavriatopoulou[b], Jordan M. Cloyd[a], Timothy M. Pawlik[a,*]

Surg Oncol 2019

- Disappearance does not mean not visible peri - operatively

meticulous intraoperative assessment
- *full liver mobilization*
- *visual inspection*
- *palpation*

- Overall, macroscopic residual disease is discovered in 11 – 45 % of patients at the time of surgery

- Combination of palpation and IOUS : detection rate up to 60 %

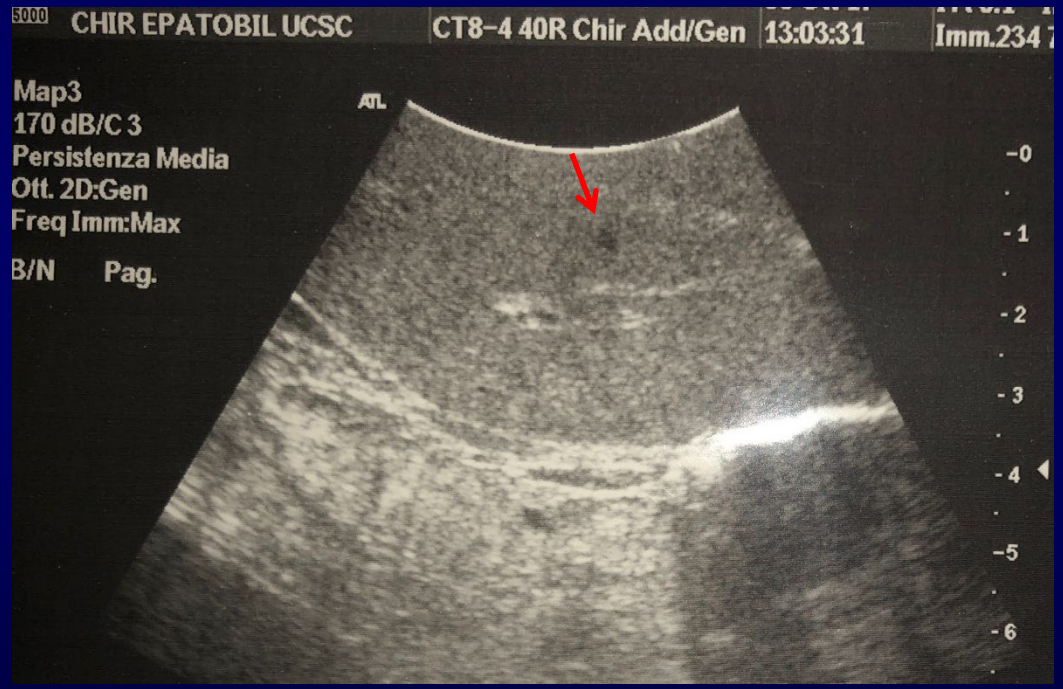

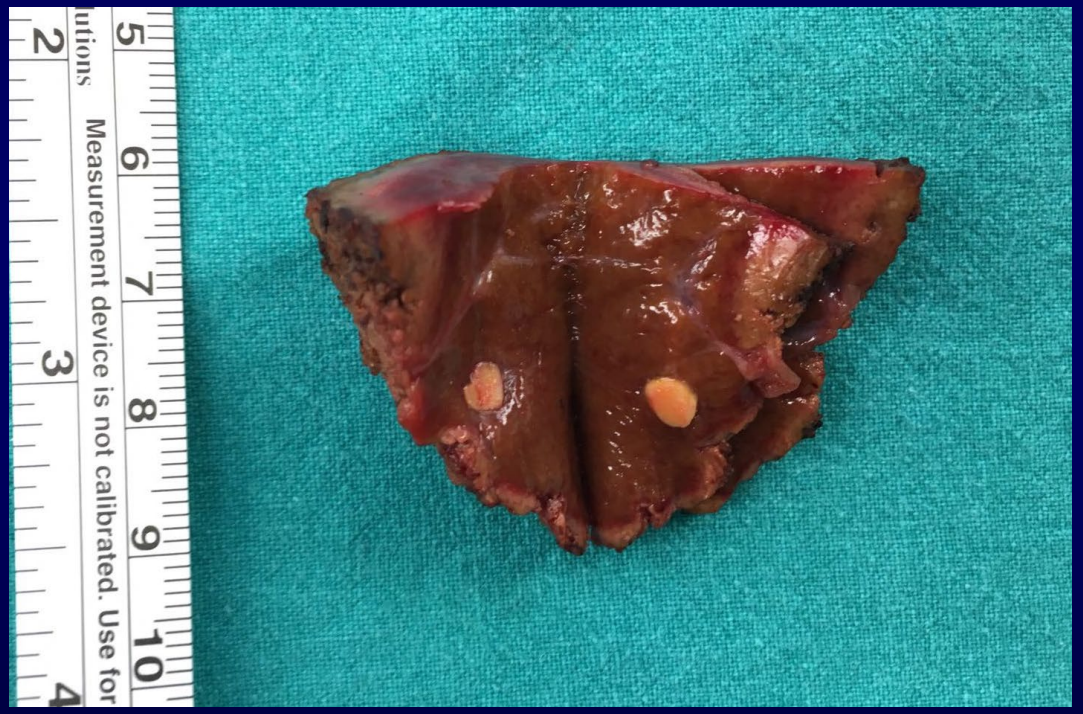



Liver, Pancreas and Biliary Tract

Contrast-enhanced intraoperative ultrasound improved hepatic recurrence-free survival in initially unresectable colorectal cancer liver metastases

Dig Liv Dis 2024

HuiFang Li[a,b,1], Ming Shi[a,b,1], Xingzhang Long[a,c,1], Pinzhu Huang[d], Chuan Peng[a,c], Wei He[a,b], Yuhong Li[a,e], Binkui Li[a,b], Yunfei Yuan[a,b], JiLiang Qiu[a,b,*], Ruhai Zou[a,c,**]

- patients with multiple CRLM gained a significant benefit regarding staging completeness with both IOUS and CE-IOUS

46 yrs-old female

CT after chemotherapy (FOLFOXIRI + Bevacizumab , 5 courses)

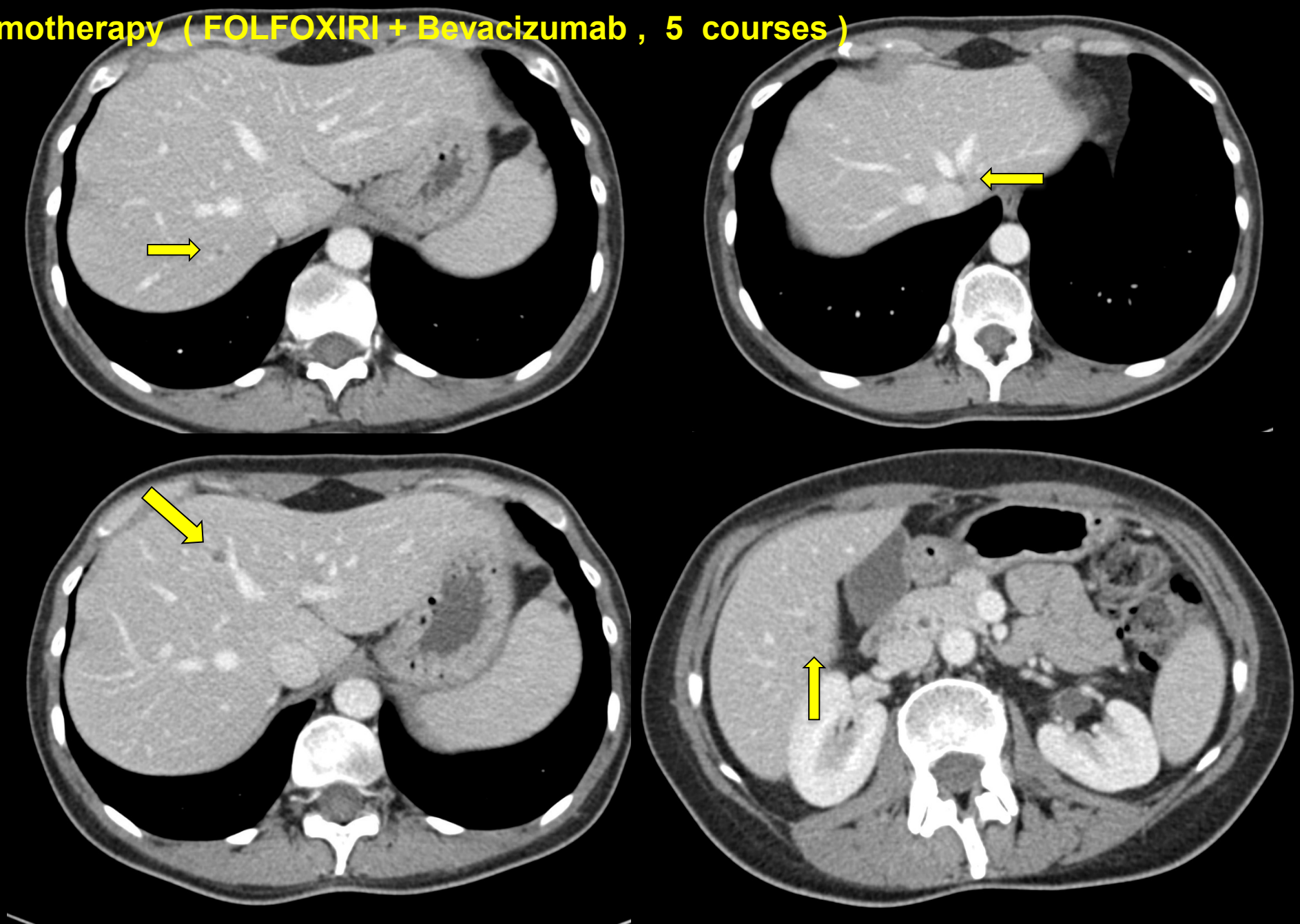

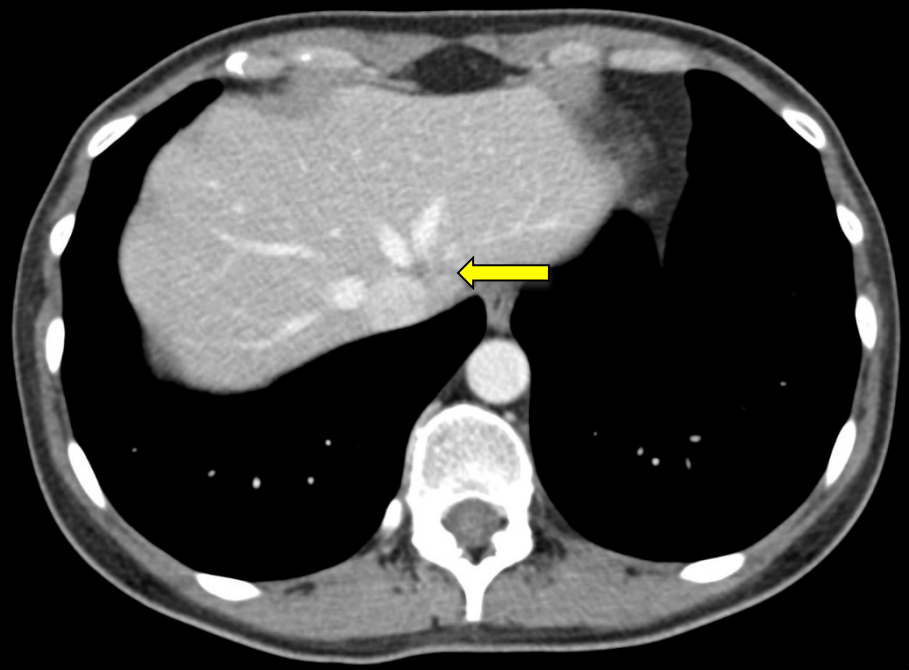

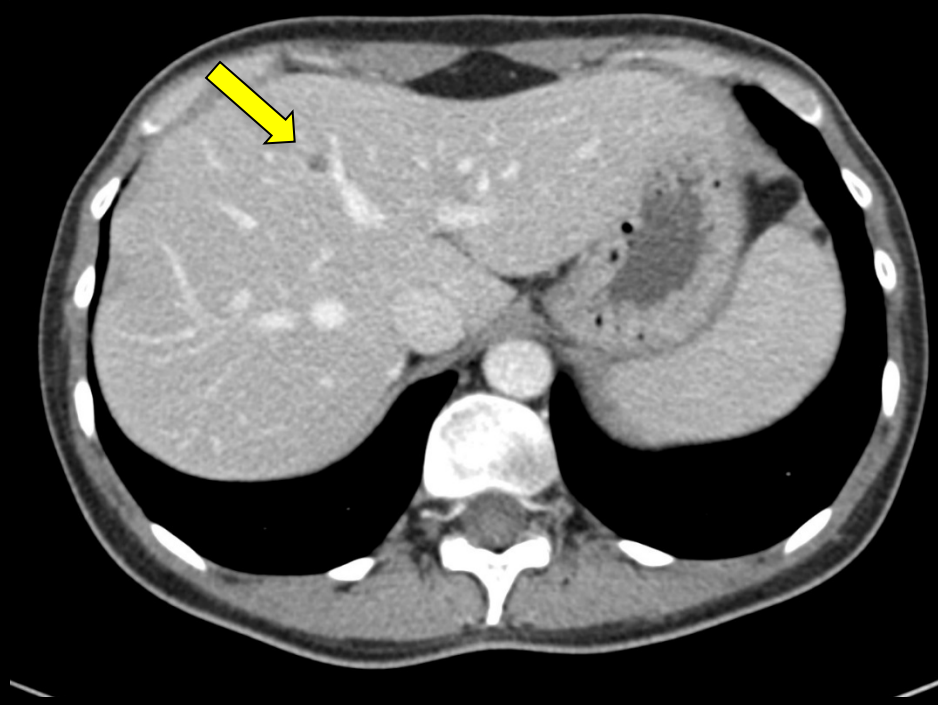

Intraoperative Ultrasound Staging for Colorectal Liver Metastases in the Era of Liver-Specific Magnetic Resonance Imaging: Is It Still Worthwhile?

J Oncol 2019

Serena Langella,[1] Francesco Ardito,[2] Nadia Russolillo,[1] Elena Panettieri,[2] Serena Perotti,[1] Caterina Mele,[2] Felice Giuliante,[2] and Alessandro Ferrero[1]

- 489 pts resected after preoperative CHT

- DLM in 52 pts (10.6 %)

In 38 pts (73 %) DLM were found intraoperatively

Disappearance of metastases after chemotherapy

- After accurate preoperative imaging and intraoperative evaluation, some DLM remain undetectable

Benoist et al. JCO 2006; Tan et al. J Gastrointest Surg 2007; Adam et al. JCO 2008; Elias et al. Ann Surg Oncol 2007; Tanaka K et al Ann Surg 2009; Auer RC et al Cancer 2010; Van Vladder M et al. J Gastrointest Surg 2010

Management of disappearing lesions after chemotherapy for colorectal liver metastases: Relation between detectability and residual tumors

Keigo Tani MD, PhD[1] | Junichi Shindoh MD, PhD[1,2] | Nobuhisa Akamatsu MD, PhD[1] | Junichi Arita MD, PhD[1] | Junichi Kaneko MD, PhD[1] | Yoshihiro Sakamoto MD, PhD[1] | Kiyoshi Hasegawa MD, PhD[1] | Norihiro Kokudo MD PhD[1]

J Surg Oncol 2018

- 82 patients with 111 DLM on CT
- The probability of residual disease was > 70 % for DLM detected by EOB-MR
- DLM not identified by EOB-MR and CE-IOUS : residual disease ~ 7 %

Management of disappearing metastases

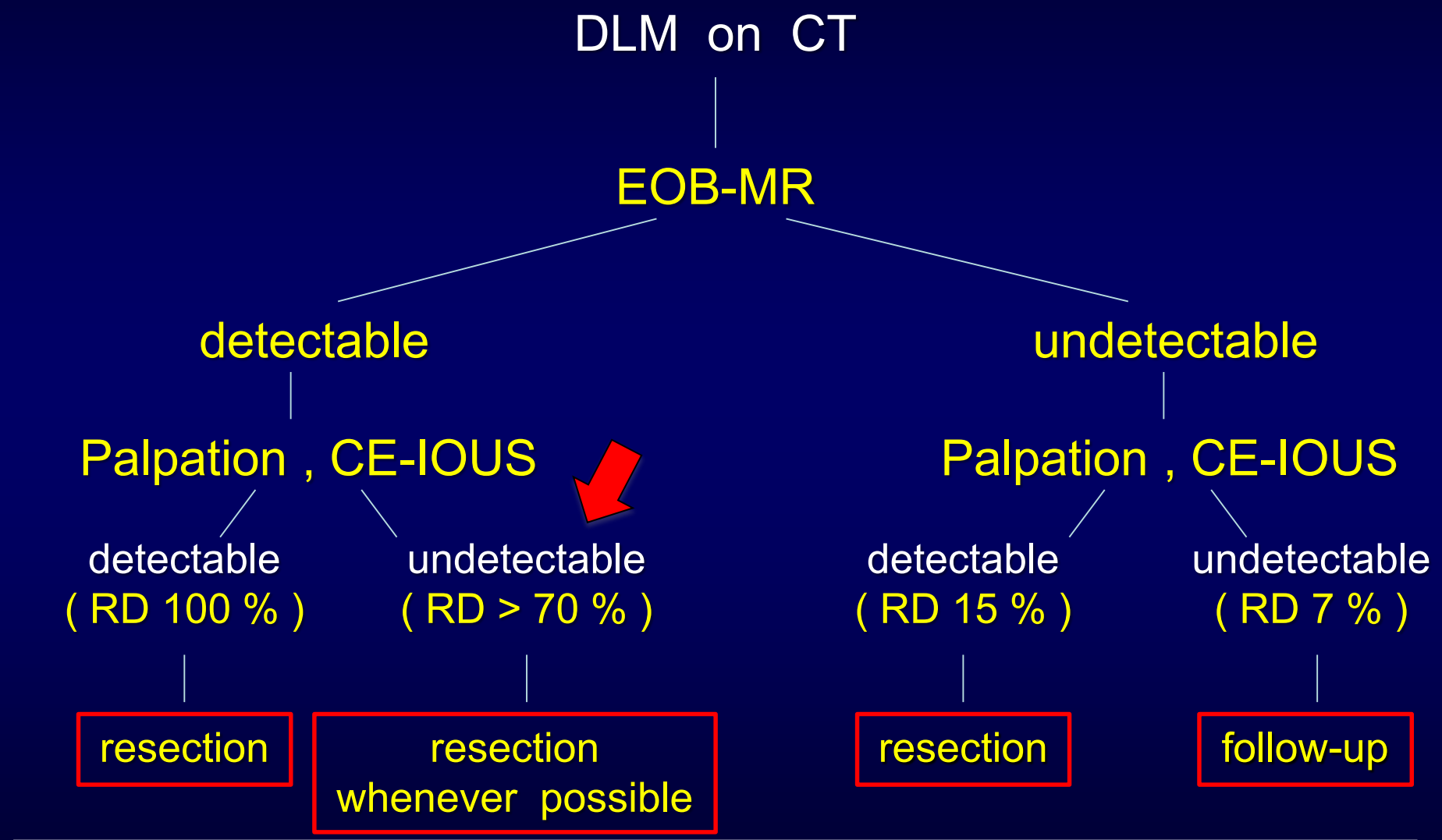

Tani J Surg Oncol 2018

Eradication of Missing Liver Metastases After Fiducial Placement

Guillaume Passot[1] · Bruno C. Odisio[2] · Daria Zorzi[1] · Armeen Mahvash[2] · Sanjay Gupta[2] · Michael J. Wallace[2] · Bradford J. Kim[1] · Suguru Yamashita[1] · Claudius Conrad[1] · Thomas A. Aloia[1] · Jean-Nicolas Vauthey[1] · Yun Shin Chun[1]

J Gastrointest Surg 2016

35 patients (2005 – 2015) → 41 marked lesions

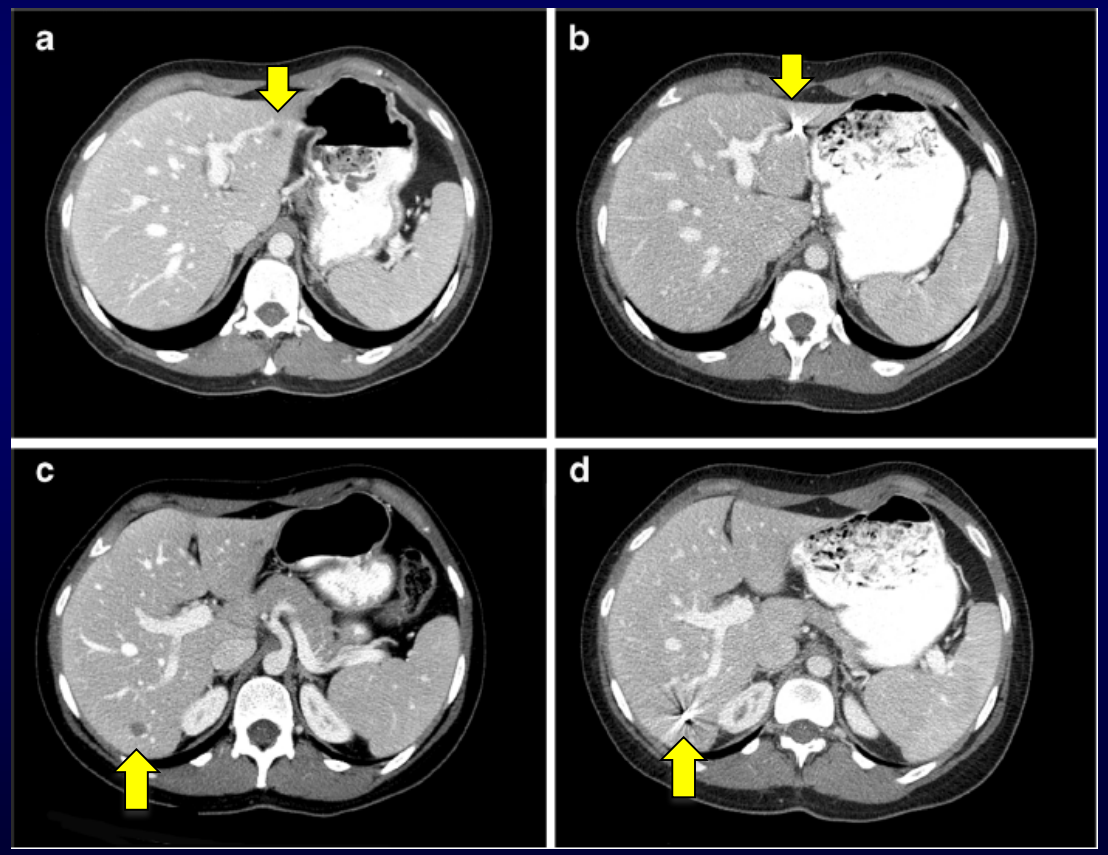

Sliced liver hepatectomy: a new type of scaffold-sparing hepatectomy for multiple bilobar colorectal liver metastases

Surg Oncol 2025

Guido Torzilli [a,b,*,1], Jacopo Galvanin [b,1], Giulia Mauri [b], Guido Costa [a,b], Bruno Branciforte [b], Flavio Milana [b], Angela Palmisano [b], Fabio Procopio [a,b]

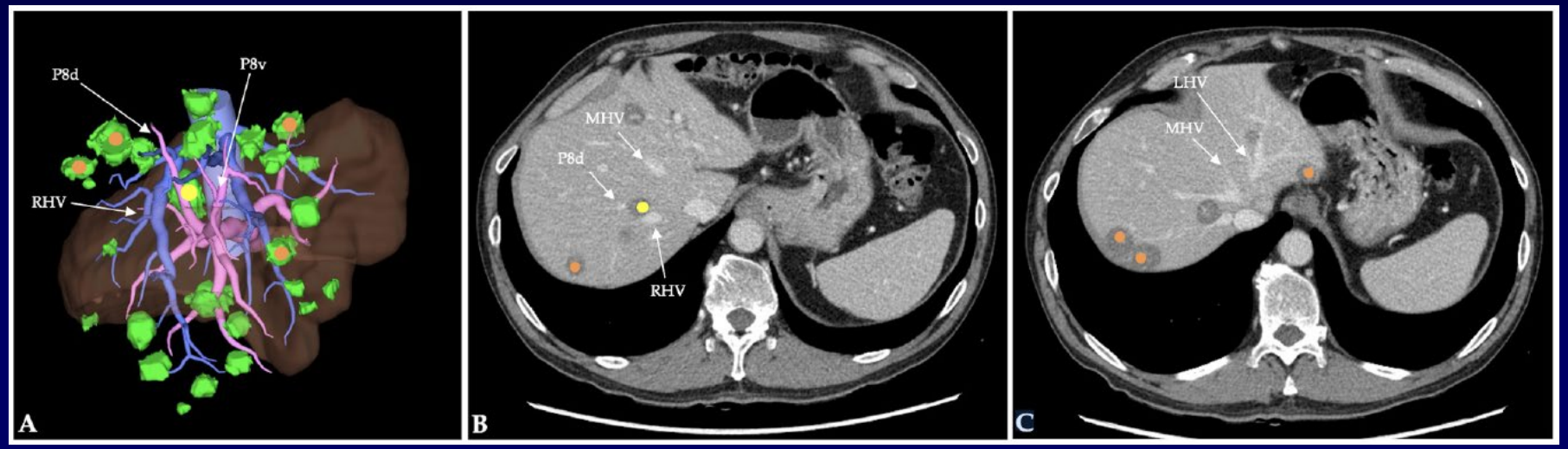

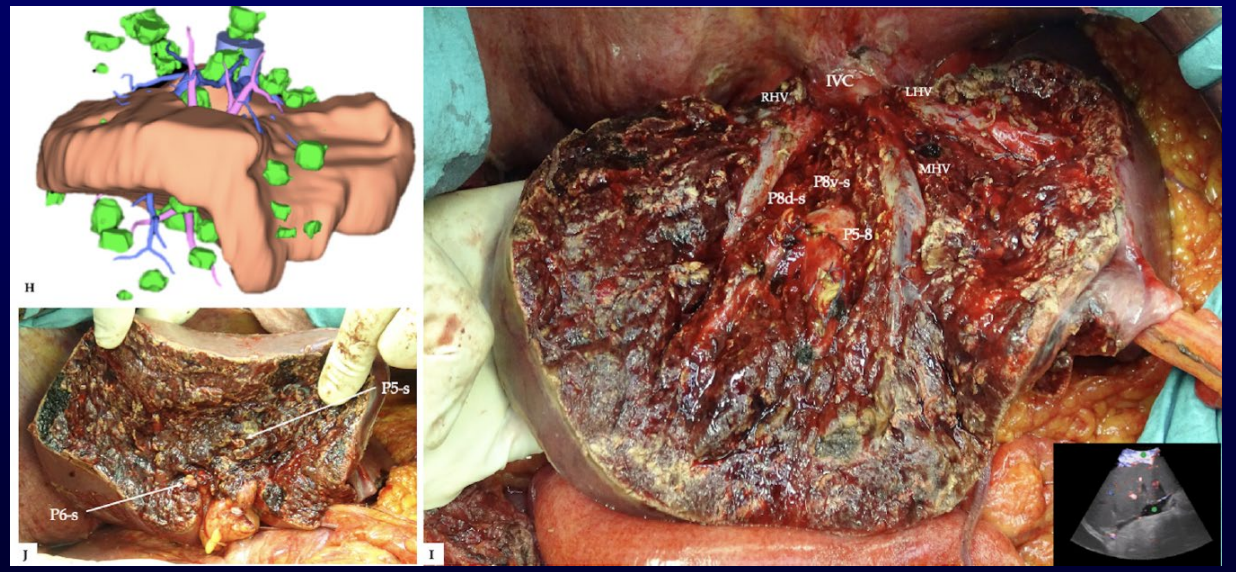

Ultrasound-based navigation for open liver surgery using active liver tracking

Int J Comput Assist Radiol Surg. 2022

Jasper N. Smit[1] · Koert F. D. Kuhlmann[1] · Oleksandra V. Ivashchenko[1,2] · Bart R. Thomson[1,3] · Thomas Langø[4,5] · Niels F. M. Kok[1] · Matteo Fusaglia[1] · Theo J. M. Ruers[1,6]

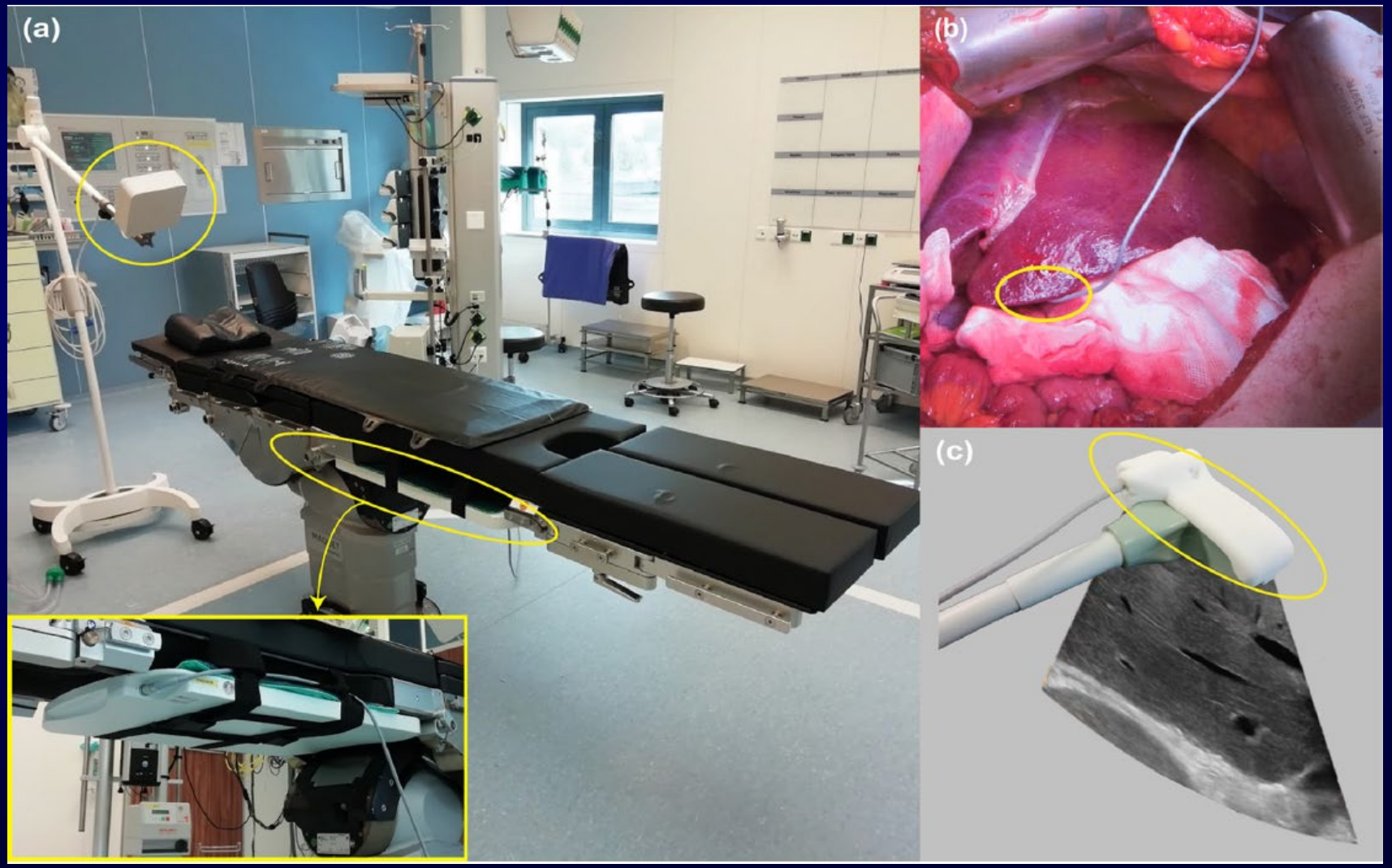

A surgical navigation system to aid the ablation of vanished colorectal liver metastases

Br J Surg 2024

Karin Olthof[1,*], Jasper Smit[1], Matteo Fusaglia[1], Niels Kok[1], Theo Ruers[1,2] and Koert Kuhlmann[1]

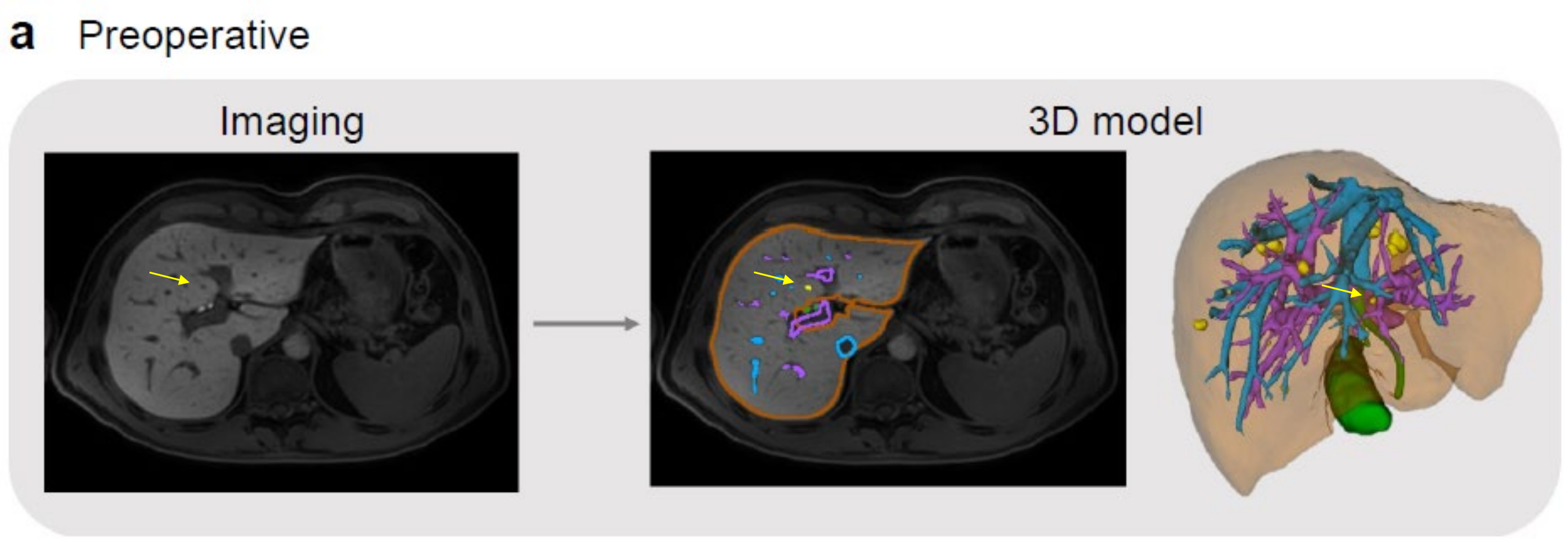

A surgical navigation system to aid the ablation of vanished colorectal liver metastases

Br J Surg 2024

Karin Olthof[1,*], Jasper Smit[1], Matteo Fusaglia[1], Niels Kok[1], Theo Ruers[1,2] and Koert Kuhlmann[1]

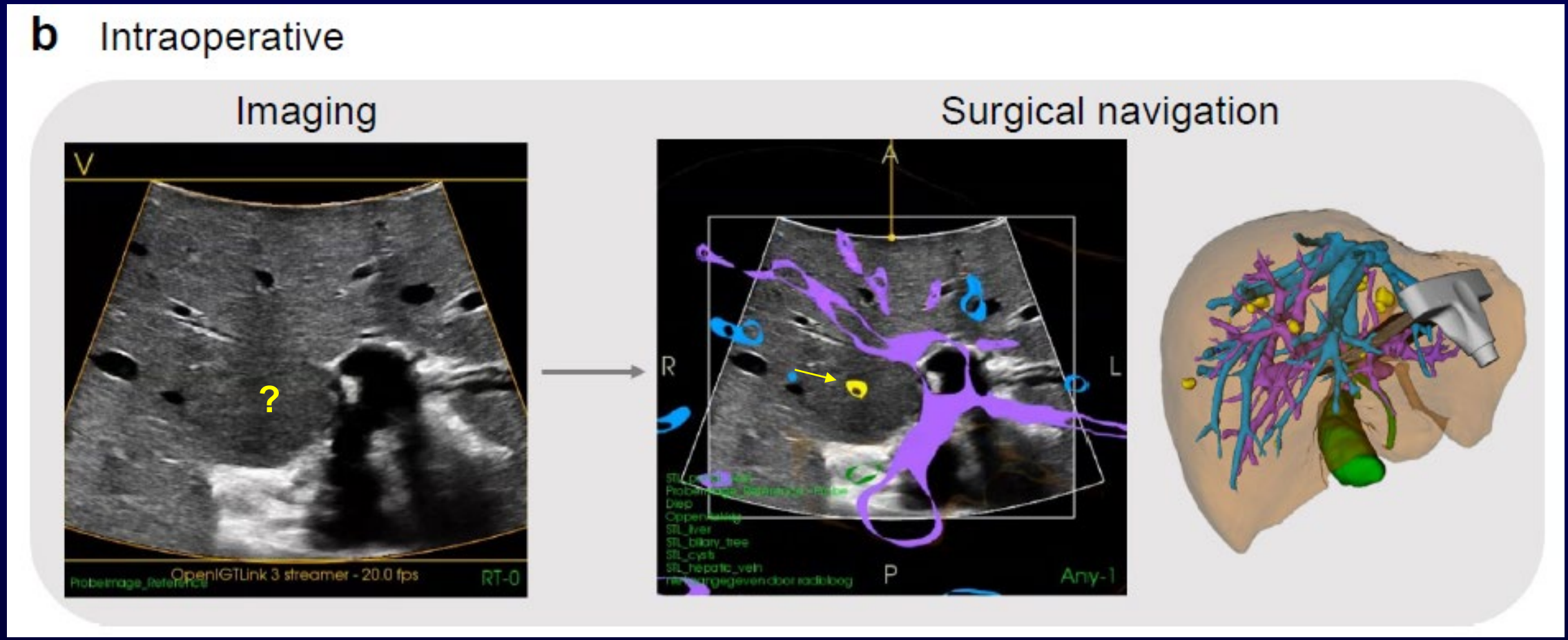

A surgical navigation system to aid the ablation of vanished colorectal liver metastases

Br J Surg 2024

Karin Olthof[1,*], Jasper Smit[1], Matteo Fusaglia[1], Niels Kok[1], Theo Ruers[1,2] and Koert Kuhlmann[1]

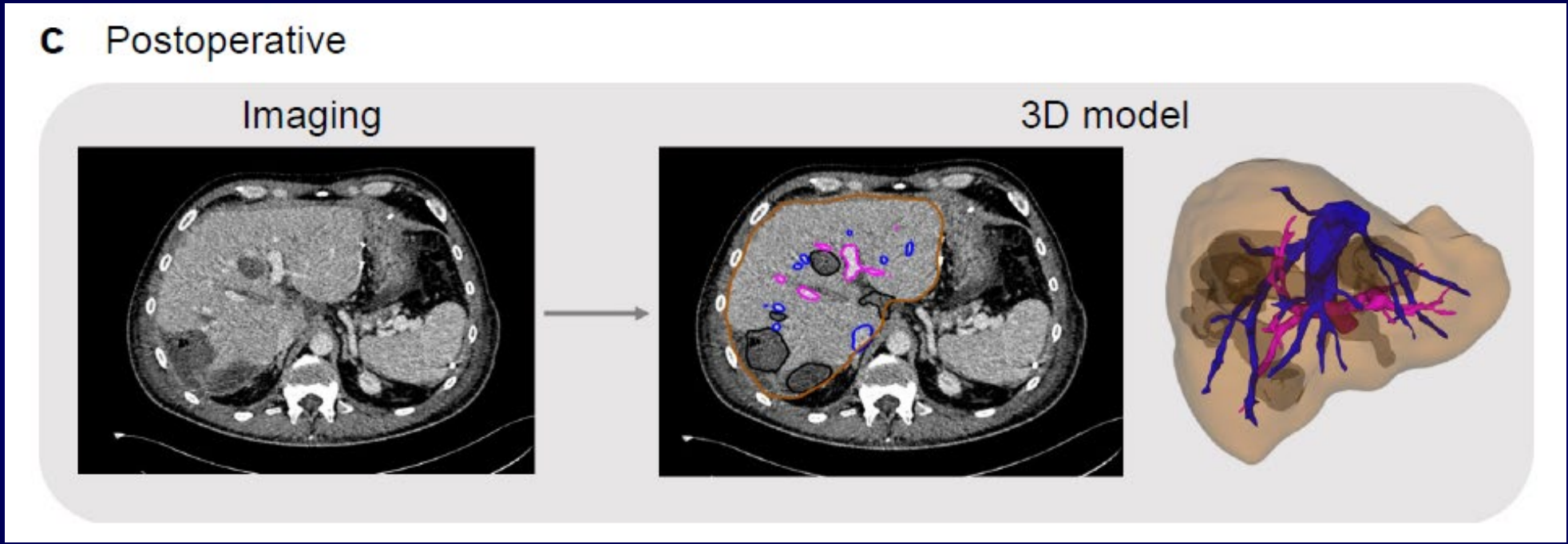

Limitations

- **target accuracy : 8.5 mm**
- **available only for open surgery**